EYE - DAWN
DR.AGARWALS
NEWSLETTER
RISE WITH KNOWLEDGE
OCTOBER 2026
BY POST GRADUATES

EYE-CONIC CASE
Glimpse of an enticing case scenario

LIMBAL DERMOID: FROM EXCISION TO RECONSTRUCTION
-Dr Afsha

A 13-year-old female presented with diminution of vision and a foreign-body sensation in the left eye for one month. Visual acuity was 6/9 in the right eye and 2/60 in the left eye. Refraction in the left eye was +6.00/−4.00 × 130°, with near correction of +9.00/−4.00 × 130°, achieving N10 at 10 cm, consistent with high hyperopic astigmatism with refractive amblyopia. A] Slit-lamp examination revealed a well-demarcated, dome-shaped, elevated yellowish-white mass at the inferotemporal limbus, extending from 3 to 6 o'clock and measuring approximately 4 × 5 mm, 2mm in cornea and 3mm in sclera. The lesion straddled the limbus, extending onto the adjacent peripheral cornea and sclera, with a smooth, opaque surface and fine vellus hairs arising from the epithelial surface, consistent with a limbal dermoid .B] AS-OCT demonstrating a well-defined, dome-shaped hyperreflective limbal lesion with extension onto the adjacent cornea and posterior shadowing.

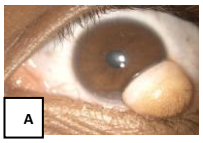

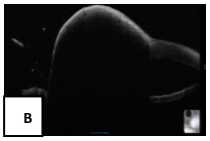

Limbal dermoid is a congenital benign mass at the inferotemporal limbus, often containing hair, fat, or cartilage and linked to Goldenhar syndrome. Larger or visually significant lesions require excision, ranging from keratectomy to keratoplasty with graft support, while small stable ones are observed.

SURGICAL RECONSTRUCTION

The patient underwent limbal dermoid excision with simultaneous Small Incision Lenticule Extraction (SMILE)-derived lenticule grafting, fibrin glue fixation, and corneal tattooing using Indian ink. Following excision of the dermoid, the resultant corneal and limbal defect along with adjacent scleral involvement was reconstructed using a SMILE-derived corneal lenticule, which was secured to the recipient bed with fibrin glue, effectively covering both corneal and scleral surfaces.. Corneal tattooing with Indian ink was performed during the same sitting to camouflage the residual corneal opacity and enhance the cosmetic appearance. The patient was subsequently followed clinically, with postoperative medications and documentation on day 1 and at 3 weeks.

POST OPERATIVE DAY 1

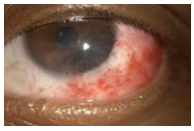

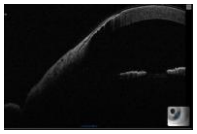

POST OPERATIVE 3 WEEKS

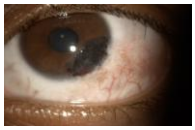



EYE-OPENER
Lets brush-up our basics

Physics of pinhole vision
-Dr Raghavender

Optical principle :

A pinhole acts as a filter restricting the aperture of the eye allowing only a narrow beam of central light rays to reach the retina. The key concept is the Circle of Confusion. When the eye is not perfectly focused, rays from a point object do not converge to a single point on the retina and instead form a finite blur circle. The pinhole decreases the size of circle of confusion and minimises blur and other higher order aberrations by excluding marginal rays.

Ray diagram :

Wide aperture —> More marginal rays —> Larger blur (circle of confusion) on the retina
Small aperture —> Mainly central rays —> Smaller circle of confusion producing sharper image

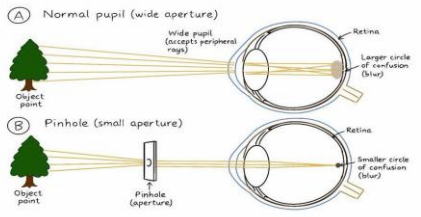

Challenges of small and large pinhole

Small pinhole :

1) Diffraction : As the aperture becomes progressively smaller light rays bend around the aperture after passing through it leading to increase in blurring.
2) Amount of light entering the eye is decreased leading to:
   a) Poor night vision
   b) Diminished overall contrast and sharpness

Large pinhole:

1) Defocus: As the aperture becomes progressively larger, more peripheral rays enter leading to increase in blurring.
2) Amount of light entering the eye is increased leading to :
   a) Photophobia
   b) Glare
   c) Squinting of eyes and headache

Thus there is an optimal aperture at which there is a balance between minimising defocus blur and avoiding excessive diffraction which is roughly 1.0mm - 1.2mm.

Clinical relevance :

Improvement with pinhole suggests that reduced vision has an optical component such as refractive error or any corneal irregularity.

Little or no improvement may suggest that reduced vision probably has a structural component such as retinal, macular or optic nerve pathology.

EYE-WORTHY SNAP
Captured clinical findings

OPHTHALMIA NODOSA
- Dr Aparna

A 47-year-old male presented to the OPD with a history of ocular exposure to an insect 20 days prior, followed by persistent ocular redness and foreign body sensation in the right eye.

A

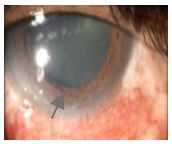

B

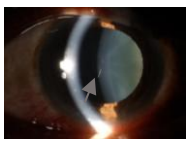

A – Slit-lamp examination revealed multiple caterpillar setae embedded within the RE corneal stroma, with additional setae extending into the anterior chamber. Localized inferior ciliary congestion with tortuous episcleral vessels was noted.
B - Slit-lamp examination demonstrated caterpillar setae embedded in the anterior lens capsule

C

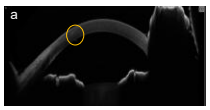

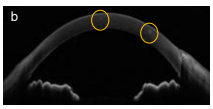

C –Anterior segment OCT demonstrates (a) hyperreflective linear structures corresponding to embedded caterpillar setae within the corneal stroma and anterior chamber, (b) round hyperreflective focus within the corneal stroma, representing the transverse cross-section of an embedded caterpillar hair.
Ophthalmia nodosa is an ocular inflammatory disorder caused by penetration and migration of caterpillar setae, producing mechanical and toxin-mediated inflammation. Clinical manifestations range from conjunctivitis and keratoconjunctivitis to keratitis, anterior uveitis, iris nodules, focal cataract and, rarely, vitreoretinal involvement. Slit-lamp examination is essential for identifying retained setae, while AS-OCT/UBM may help localize deeply embedded setae. Management includes meticulous removal of accessible setae, ocular irrigation, topical corticosteroids, antibiotics when indicated, and lubricants. Intraocular or lenticular setae may require surgical removal. Long-term follow-up is essential because retained intracorneal setae may migrate intraocularly and cause delayed complications.

EYE QUEST
To tease your brain a little

SEE, SQUINT, SOLVE
- Dr Misba

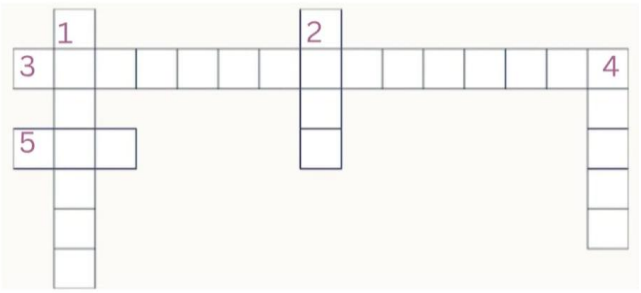

Across

3. I bring retinal capillary hemangioblastomas with feeder vessels and mutations in chromosome 3p

5. I decorate iris with nodules, cause optic pathway gliomas and drop an S shaped ptosis in the eyelid. Who am I?

Down

1. Optic atrophy, diabetes insipidus, diabetes mellitus, deafness all in one package!

2. I serve egg yolk vitelliform lesion on your macula, leaving you with a crashed Arden ratio on EOG.

4. I dim your eyes with RP and mute your ears with deafness

STUDENT LEAD

DR. AFSHA

DR APARNA

STUDENT MEMBERS

DR TREESA

DR DHANNYA

DR RAGHAVENDER

SUPERVISING EDITOR

DR DHIVYA ASHOK KUMAR

www.dragarwal.com
No.222, TTK Road, Alwarpet, Chennai, Tamil Nadu 600018.